

Novel MRI Changes After Gamma Knife for Hypothalamic Hamartoma in a Child

Krystal Thorington, Frederick A. Zeiler, Patrick J. McDonald

Can J Neurol Sci. 2012; 39: 541-543

Hypothalamic hamartomas (HH) are rare lesions of ectopic neural tissue arising from the wall of the hypothalamus. Patients with HH can present with gelastic seizures, precocious puberty or both¹. Seizures are usually progressive and accompanied by worsening behavioral problems and developmental delay¹.

Stereotactic radiosurgery (SRS) has been shown to be safe and effective, resulting in improvement in seizures and halting tumor progression. Gamma Knife (GK) radiosurgery in the treatment of hypothalamic hamartoma has reported Engel Class 1 seizure status of up to 60%, with improvement in behavioral status in some cases². Post-treatment magnetic resonance (MR) imaging as reported in the literature has not demonstrated significant changes within the treated areas of a HH.

The authors report the case of a four year-old boy with a symptomatic hypothalamic hamartoma treated with GK radiosurgery. Serial MR imaging after treatment revealed significant and progressive edema and swelling at the treatment site, with increased T2 signal change and gadolinium uptake lasting one year after treatment and eventually resolving spontaneously. Although not accompanied by clinical worsening, these changes have not been previously reported in SRS for HH.

CASE REPORT

History and Examination

A 2 ½ -year-old boy presented with a history of spells of inappropriate laughter, increasing in frequency over the past several months and more recently associated with staring episodes and periods of lethargy following these attacks. A magnetic resonance scan of the brain showed a 2.0 x 2.0 cm, iso-intense to grey matter, non-enhancing mass arising from the left inferomedial wall of the hypothalamus (Figure 1A). A diagnosis of gelastic seizures secondary to a hypothalamic hamartoma was made.

After an initial response to treatment with carbamazepine, the frequency and intensity of the seizures increased over the next 18 months, with an average of 25 seizures daily. This was accompanied by both behavioral problems and loss of intellectual milestones. Given the deterioration, we proceeded with Gamma Knife SRS.

Treatment and Post-treatment Course

Under general anesthetic, the now four year-old boy underwent GK radiosurgery, receiving 16 Gy to the 50% isodose line (Figure 1). Optic nerve dosing was less than 10 Gy. There were no immediate side effects of the treatment. Within three months of undergoing radiosurgical treatment, there was a

significant reduction in seizure frequency, from 25 seizures per day to 1-2. In addition, significant behavioral improvement was noted.

Repeat MR imaging six months post-treatment showed a slight increase in the size of the hamartoma with new findings of increased T2-weighted signal intensity and heterogeneous uptake of gadolinium in the central portion of the lesion. Further imaging at nine months showed a further increase in the size of the lesion, with more pronounced T2 signal change and contrast uptake with obliteration of the adjacent cisterns (Figure 2B). Imaging at one year post-treatment showed partial resolution of these findings, with a reduction in the size of the lesion and less T2 signal change and contrast uptake (Figure 2C). The cisterns adjacent to the hamartoma were once again visible. By 16 months post-treatment, the lesion had returned to its pre-treatment size, with resolving T2 signal change and no contrast uptake but a hypointense core (Figure 2D). Throughout this period, the child remained well.

Corresponding T2 images from 6, 9, 12, and 16 months post-GK are represented in the Figure 3 (A,B,C and D respectively). The six month post-GK coronal T2 image (Figure 3A) demonstrates new T2 signal within the center of the hamartoma, likely representing edema. The sequential coronal T2 nine month (Figure 3B) and axial T2 12 month (Figure 3C) post-GK images demonstrate worsening of the T2 hyperintensity. Finally, the 16 month post-GK axial T2 (Figure 3D) image demonstrates resolving hyperintense signal within the hamartoma.

His seizures remained significantly decreased in both frequency and intensity for three years but he ultimately required surgical resection of the hamartoma when his seizures recurred. Pathologic review of the lesion after surgery confirmed the diagnosis of hypothalamic hamartoma. Currently, he is seizure free post-resection, with occasional auras.

DISCUSSION

Hypothalamic hamartomas are ectopic, non-neoplastic nodules that resemble normal gray and white matter, arising from the tuber cinereum and inferior hypothalamus¹. On MR imaging, HH's will appear as a mass isointense to gray matter on T1 and T2 weighted imaging³.

From the Section of Neurosurgery, University of Manitoba and Winnipeg Children's Hospital, Winnipeg, Manitoba, Canada.

RECEIVED JANUARY 23, 2012. FINAL REVISIONS SUBMITTED MARCH 2, 2012.
Correspondence to: Frederick A. Zeiler, Section of Neurosurgery, University of Manitoba, Health Sciences Center, GB-1 820 Sherbrook Street, Winnipeg, Manitoba R3A 1R9, Canada. Email: umzeiler@cc.umanitoba.ca

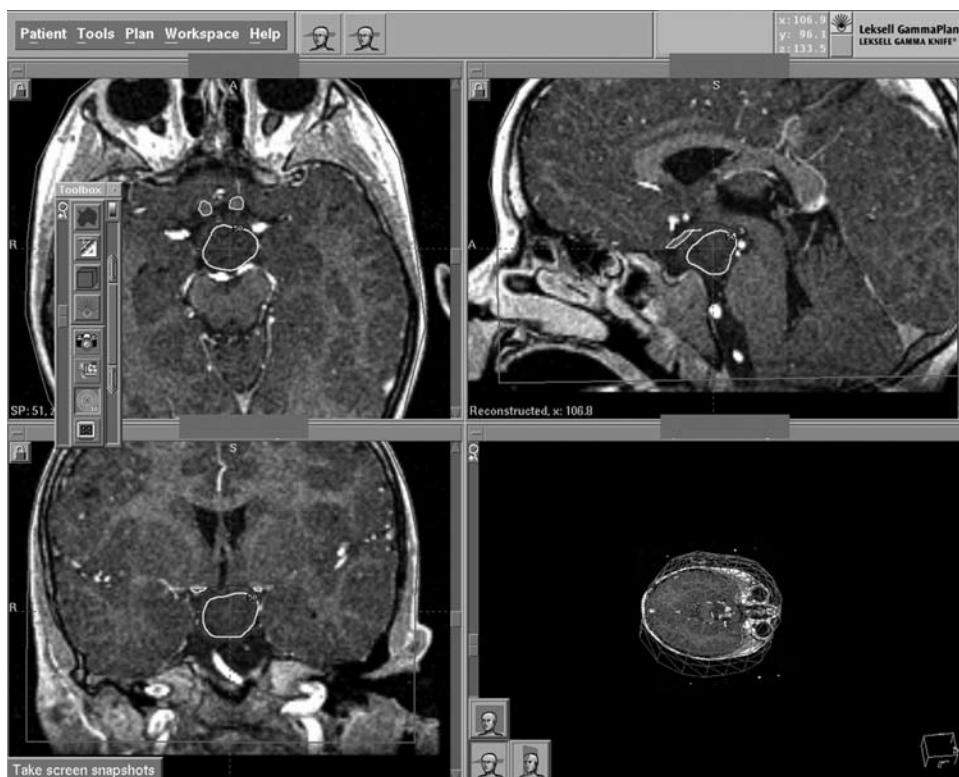


Figure 1: Gamma Knife Treatment Plan. The large white outline denotes the 50% isodose line. The small white outline indicates the optic nerves.

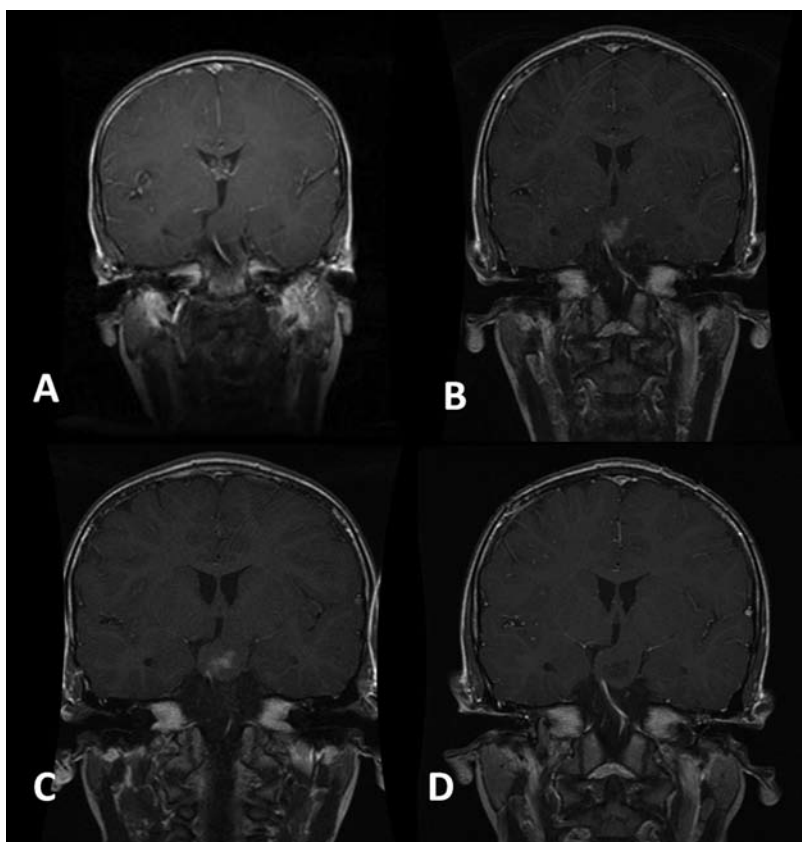


Figure 2: Coronal T1-weighted MR images Pre- and Post-Gamma Knife. MR = magnetic resonance. Image A = presentation, B = 9 months post treatment, C = 12 months post treatment, and D = 16 months post treatment.

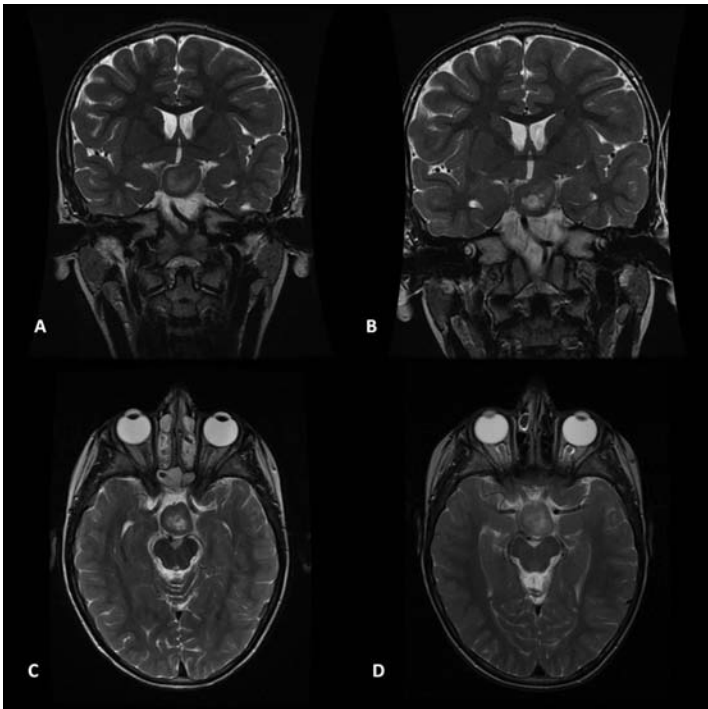


Figure 3: T2-weighted MR images Post-Gamma Knife. MR = magnetic resonance. Image A = 9 months post treatment, B = 12 months post treatment, and C = 16 months post treatment.

These lesions are relatively rare, and most often present with medically refractory epilepsy or precocious puberty¹. Gelastic seizures that are resistant to medical therapy are often the first presenting symptom of a HH, and usually progress with time, with additional seizure types manifesting to include complex partial seizures with or without secondary generalization, tonic-clonic seizures, and tonic seizures. Cognitive and behavioral decline typically accompany the increase in seizure activity.

Radiosurgery has been performed as a treatment option, with favorable results. Mathieu et al⁴ reported the outcome of nine patients treated with GK surgery, with six having their entire lesion treated. Follow-up imaging in patients revealed no significant MR imaging changes, and four patients had relief of seizure symptoms. Treatment volumes in this series were up to 1.8 cm³. In Regis' series of ten patients, all showed improvement in symptoms, with 60% Engel Class 1 seizure control rate, and behavioral improvement².

Complications post SRS for HH are scarce in the literature. Most studies report no side effects of treatment⁴. Of those complications described, the majority are worsening seizure frequency transiently post SRS². No literature sources, to the author's knowledge, have described tumor enlargement post SRS.

Magnetic resonance changes indicative of edema and which result in uptake of contrast after stereotactic radiosurgery have been described after treatment for arteriovenous malformations, meningiomas and after treatment for temporal lobe epilepsy, among others, and are thought to be related to focal breakdown of the blood brain barrier⁵. These MRI findings have been described in the epilepsy literature post-radiosurgery⁶. Such changes have not been described after treatment for HH.

To our knowledge, this represents the first known case of significant MR changes in a HH post-radiosurgery. These

changes likely represent break down of the blood brain barrier. Although the marginal dose prescription was within limits described in the literature, we hypothesize that the radiation-induced changes seen on MR may be related to the large size of our patient's lesion in comparison to those lesions described in the literature to date⁴.

Although not associated with a negative clinical change in the patient, this case underscores the need for close follow-up, including neuroimaging, of patients who have undergone stereotactic radiosurgery to treat a hypothalamic hamartoma. Though classically assumed to have a benign post-radiosurgical course, this case should outline the need for clinical suspicion and diligence in regular follow up examinations.

REFERENCES

1. Maixner W. Hypothalamic hamartomas- clinical, neuropathological and surgical aspects. *Childs Nerv Syst.* 2006;22:867-73.
2. Regis J, Bartolomei F, de Toffol B, et al. Gamma Knife surgery for epilepsy related to hypothalamic hamartomas. *Neurosurgery.* 2010;47:1343-51.
3. Arita K, Ikawa F, Kurisu K, et al. The relationship between magnetic resonance imaging findings and clinical manifestations of hypothalamic hamartoma. *J Neurosurg.* 1999;91:212-20.
4. Mathieu D, Deacon C, Pinard CA, et al. Gamma Knife surgery for hypothalamic hamartomas causing refractory epilepsy: preliminary results from a prospective observational study. *J Neurosurg.* 2010;113(Suppl):215-21.
5. Herynek V, Burian M, Kirak D, et al. Metabolite and diffusion changes in the rat brain after Leksell Gamma Knife irradiation. *Magn Reson Med.* 2004;52:397-402.
6. Chang EF, Quigg M, Oh MC, et al. Predictors of efficacy after stereotactic radiosurgery for medial temporal lobe epilepsy. *Neurology.* 2010;74(2):165-72.