Appendix

A Gross Anatomical Study of the Peripheral Nerves Associated with Reproductive Function in the Female Albino Rat

PETER REINER, JOHN WOOLSEY, NORMAN ADLER, and ADRIAN MORRISON

I. INTRODUCTION

Although there are a number of excellent anatomical studies of central neuroendocrine mechanisms, there is no single comprehensive dissection guide to the peripheral neural apparatus. The purpose of this appendix is to provide a clear description of the peripheral neuroanatomy associated with reproductive function in the female rat.

This guide deals with six major peripheral nerves: femoral, genitofemoral, pelvic, hypogastric, pudendal, and caudal cutaneous femoral. The anatomy of these nerves has been described in various species, including the albino rat, following Langley and Anderson's classic paper of 1896 (see Bradley and Teague, 1972; Carlson and DeFeo, 1965; Greene, 1968; Hebel and Stromberg, 1976; Kollar, 1952; Langworthy, 1965; Purinton *et al.*, 1973). However, gaps in these anatomical descriptions still exist. For example, some studies are primarily devoted to electrophysiology, and the accompanying anatomical descriptions were limited to the service of specific physiological experiments. Furthermore, the anatomical studies cited often are large and do not provide great detail on the peripheral genital apparatus per se. Finally, there is no single

PETER REINER and ADRIAN MORRISON • School of Veterinary Medicine, University of Pennsylvania, Philadelphia, Pennsylvania 19104. JOHN WOOLSEY • Leidy Laboratories, University of Pennsylvania, Philadelphia, Pennsylvania 19104 NORMAN ADLER • Department of Psychology, University of Pennsylvania, Philadelphia, Pennsylvania 19104.

source that pulls all of the information together in one place with accompanying diagrams for use by investigators in reproductive anatomy and physiology.

In order to facilitate understanding of the various nerves, muscles, organs, etc. discussed below, we have used the nomenclature with which most readers are familiar, that used by Greene (1968). In order to insure accuracy, we have followed Greene's terminology with the nomenclature used in *Nomina Anatomica Veterinaria* (World Association of Veterinary Anatomists, 1973), placed in parentheses, as well as using the *NAV* nomenclature in all figures. Figure 1 gives the major anatomical landmarks used for orientation and provides a useful reference throughout. Although anterior and posterior are used to facilitate comparison with the standard work by Greene, the accepted terminology for quadrupeds is cranial and caudal (World Association of Veterinary Anatomists, 1973). Anterior and posterior are now reserved for upright, bipedal animals.

II. METHODS

One hundred female rats were dissected in order to ascertain the anatomical relationships of the nerves innervating urogenital structures as well as other areas associated with reproductive function. The animals were sacrificed by overdose of anesthetic. All dissections were performed on fresh specimens in order to enhance the contrast between nervous and connective tissue. Nerves were followed from their origin at the spinal cord to the organs and muscles that they innervated with the aid of a Zeiss stereoscopic dissecting microscope. All animals were approached from the ventral aspect, and the descriptions are based upon that approach.

III. RESULTS

A. Femoral Nerve

The femoral nerve (N. femoralis) is formed by contributions from the third and fourth lumbar nerves (Greene, 1968). It travels caudolaterally, dorsal to the psoas muscle group and ventral to the body of M. iliacus. The nerve has been divided into two divisions: anterior (Ramus musculares) and posterior (N. saphenus).

The anterior division consists of those nerve branches given off to M. psoas major and M. iliacus, as the femoral nerve passes between the fascial planes separating the two (Fig. 2). It then continues on to innervate M. pectineus, passing dorsal to the external iliac vein (Vena iliaca externus), and enters the muscle on its dorsal side prior to the final branching as shown in Fig. 2.

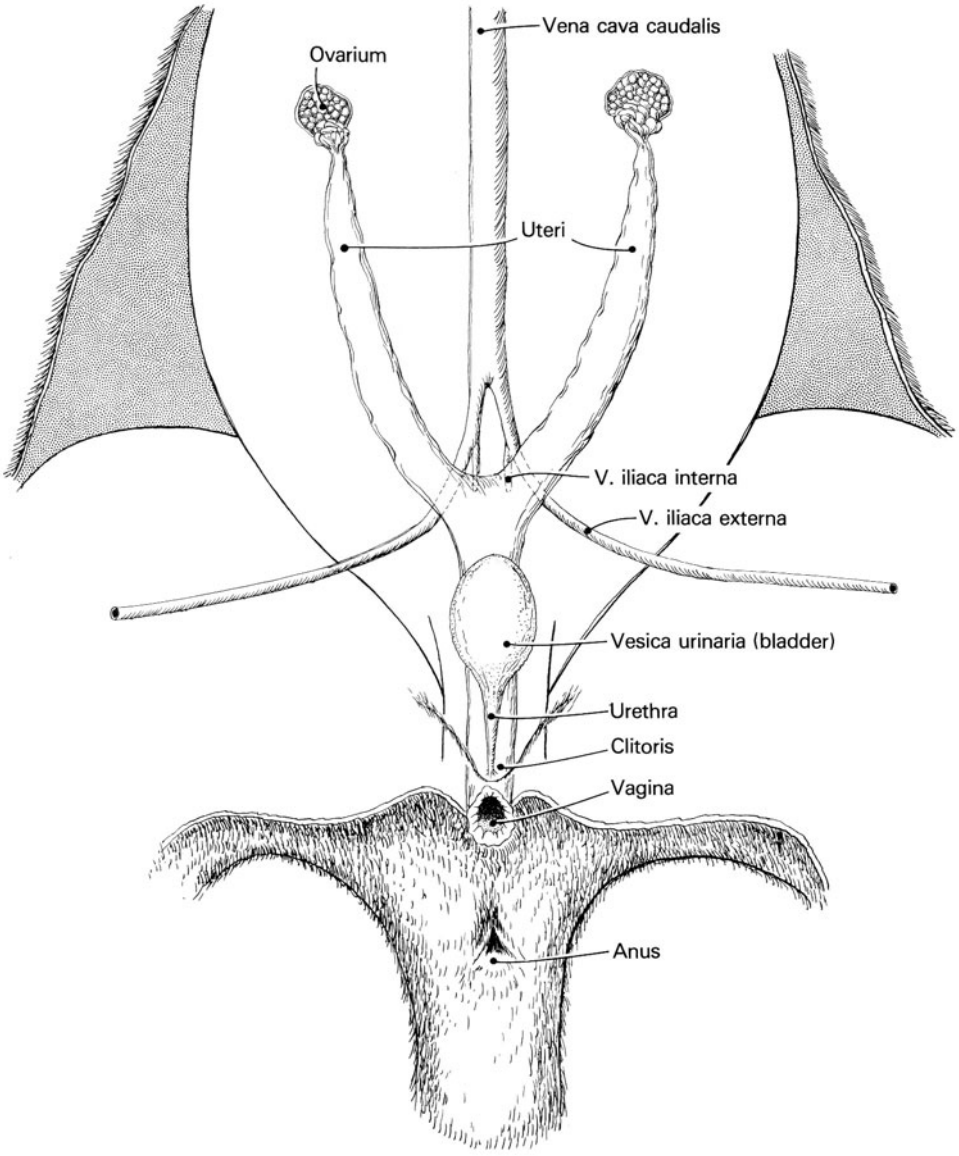

Figure 1. General anatomical landmarks, ventral view. In this and all subsequent figures, nomenclature used will be that found in *Nomina Anatomica Veterinaria* (World Association of Veterinary Anatomists, 1973). Abbreviations: A, Arteria; L, Ligamentum; M, Musculus; MM, Musculi; N, Nervus; V, Vena.

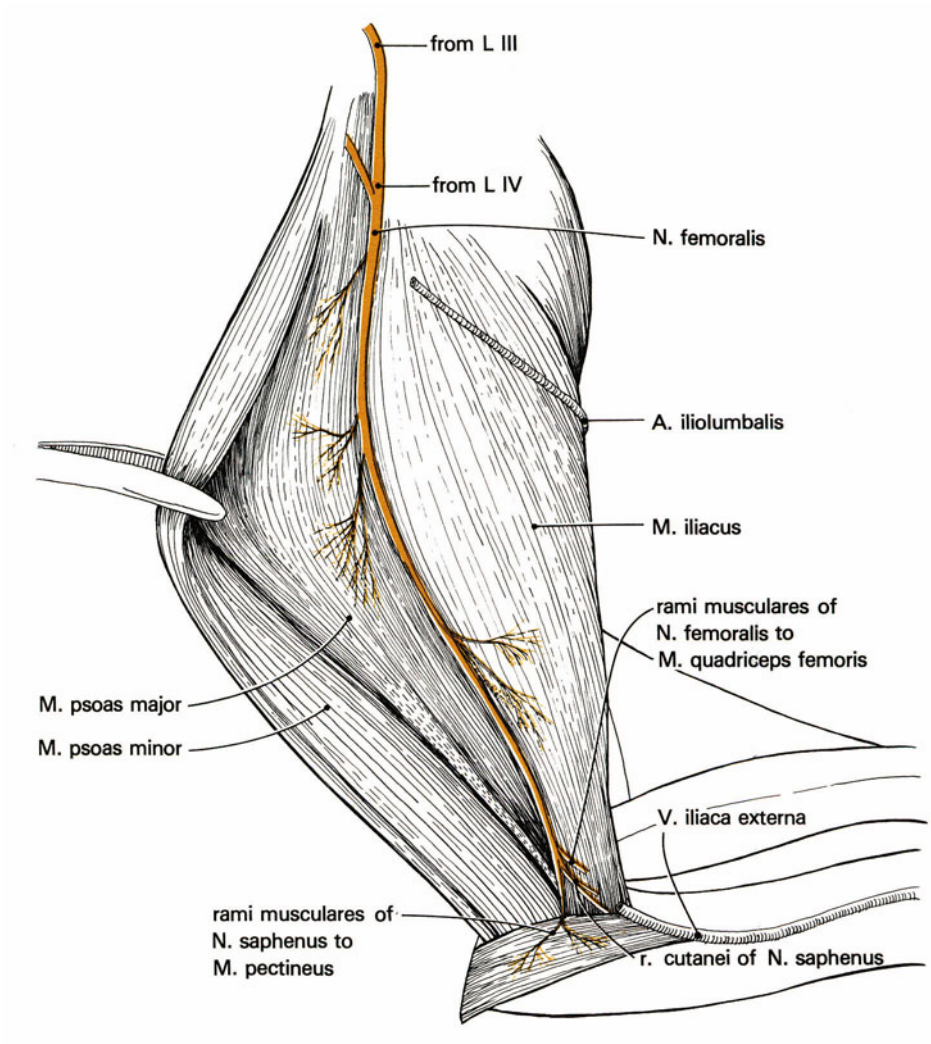

Figure 2. Nervus femoralis, ventral view, with MM. psoas reflected medially.

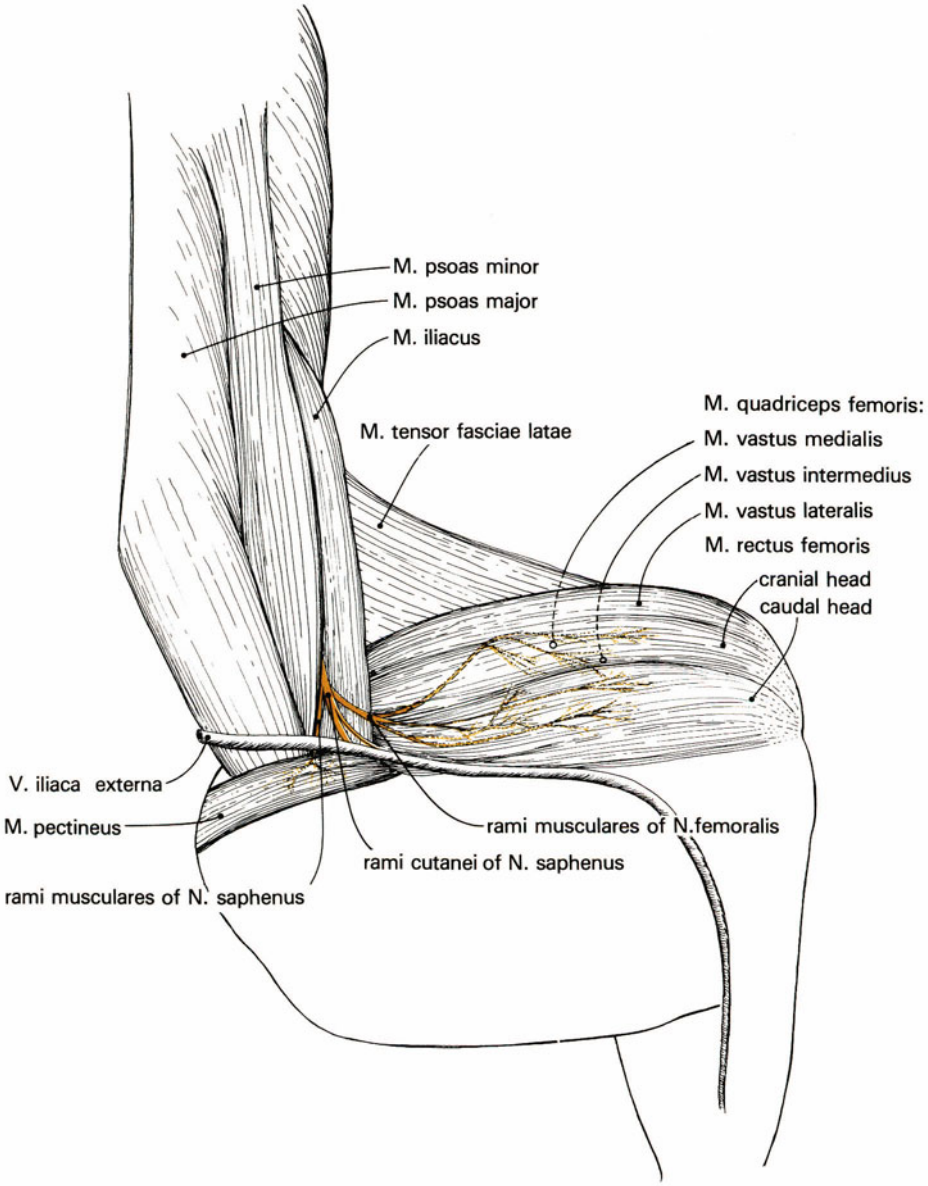

Figure 3. Nervus femoralis, ventral view, with innervation of M. pectineus and MM. quadriceps detailed.

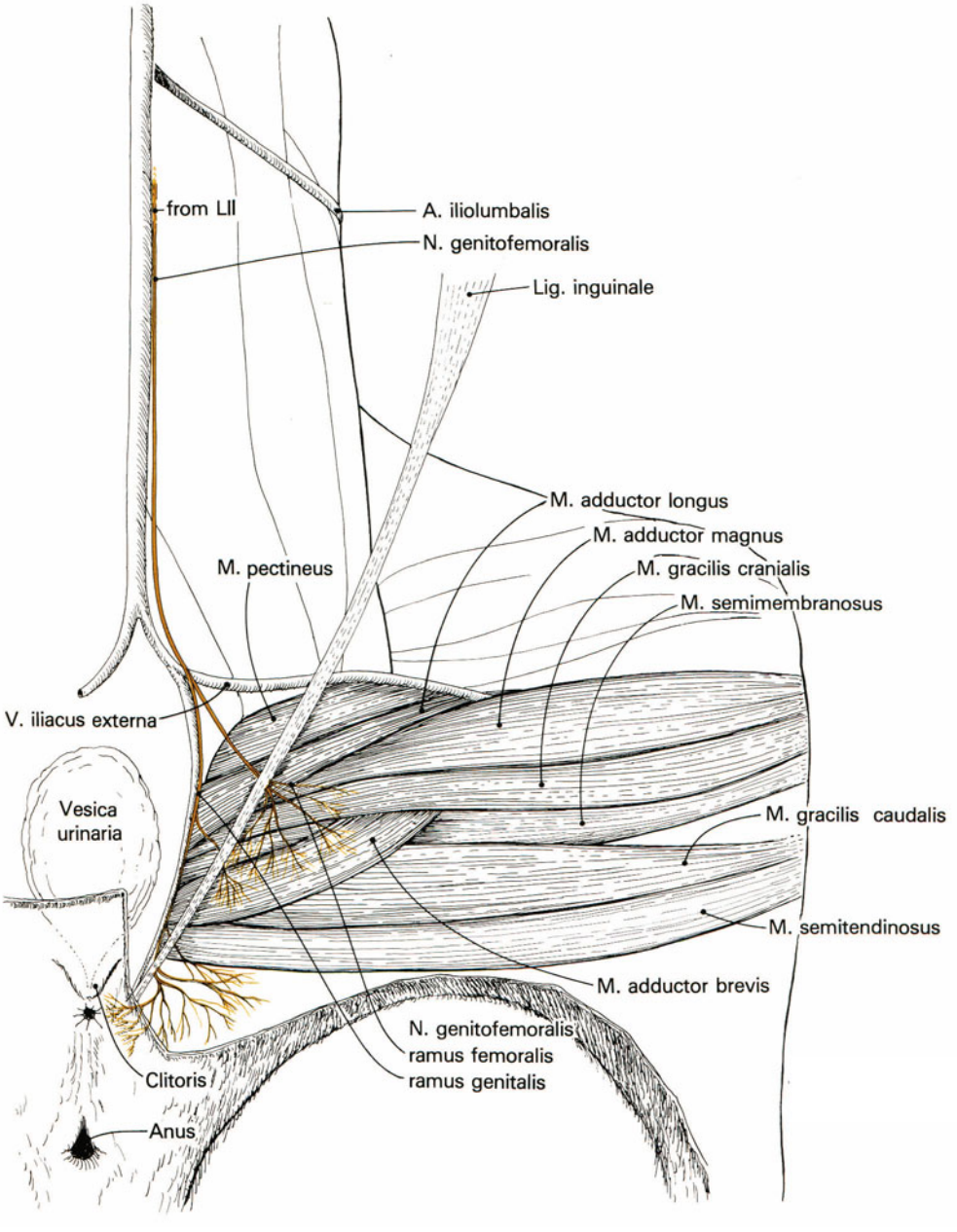

Figure 4. Nervus genitofemoralis, ventral view.

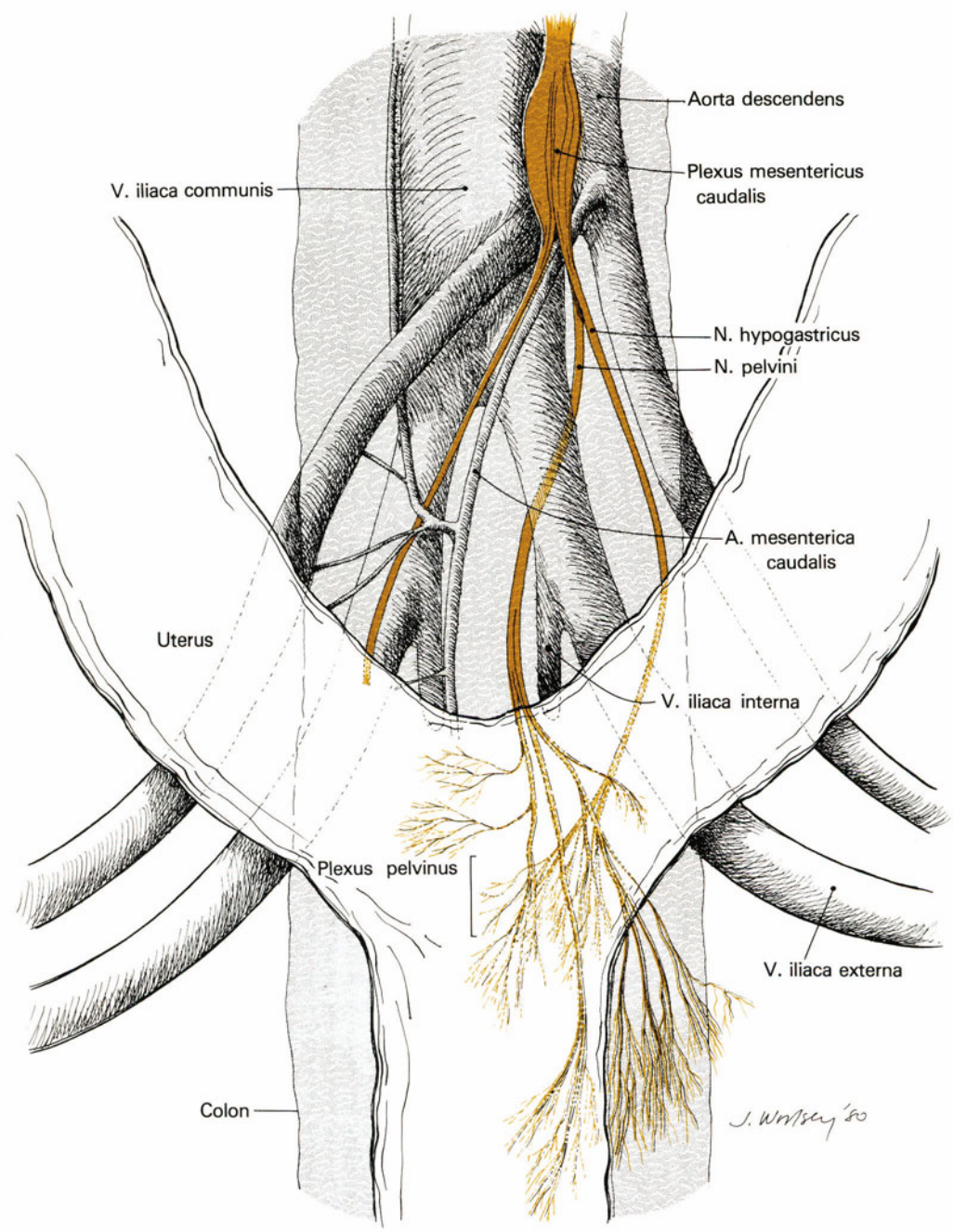

Figure 5. Plexus pelvinus, ventral view, with course of NN. pelvini and hypogastricus shown.

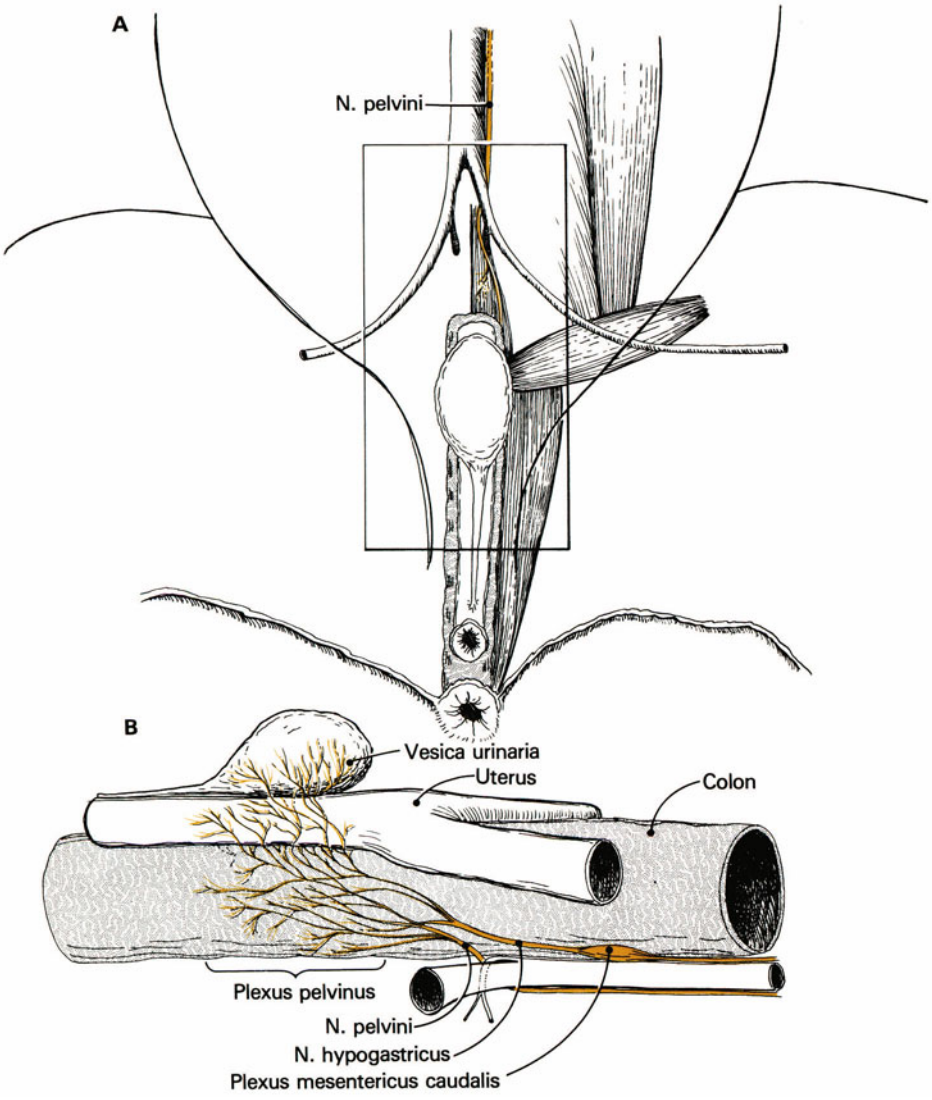

Figure 6. A, Nervus pelvini, ventral view, detail of course alongside Vena cava caudalis. B, Plexus pelvini, lateral view.

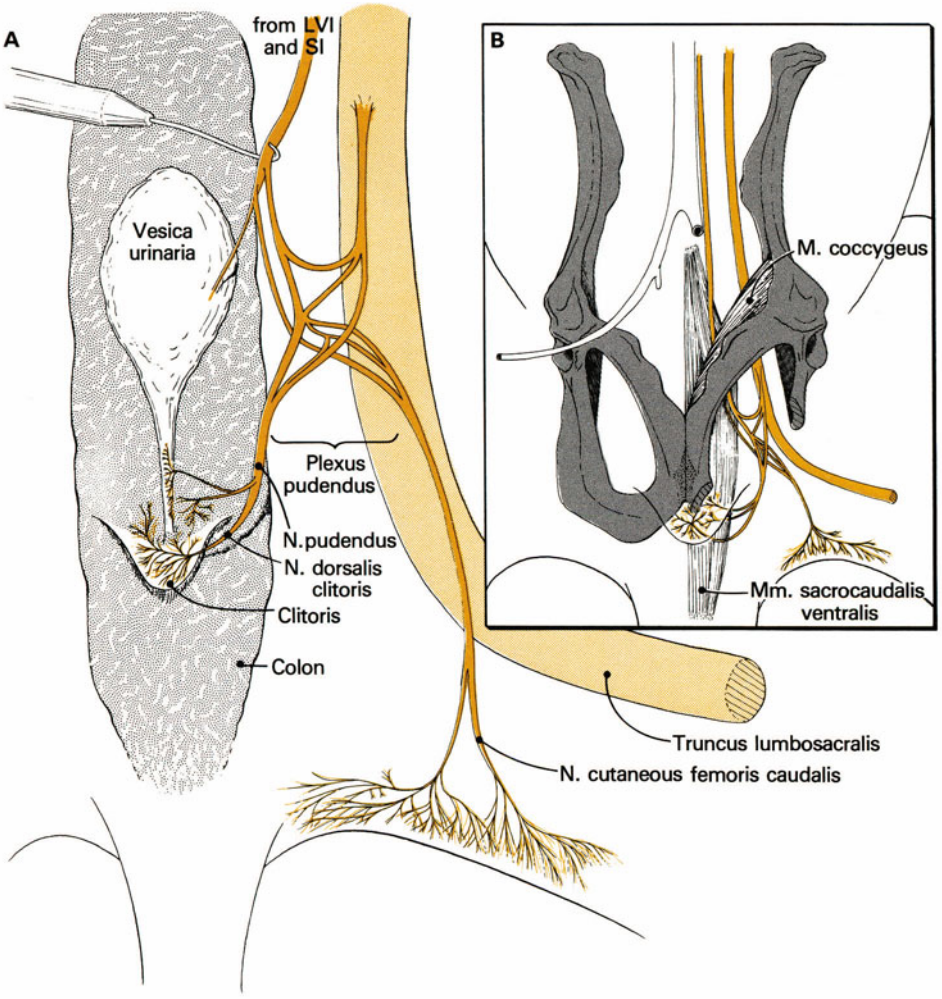

Figure 7. A, Nervus pudendus, ventral view, with detail of innervation of caudal skin (N. cutaneous femorus caudalis) and the urethra and clitoris (N. dorsalis clitoris). B, Nervus pudendus with relationship to M. coccygeus; MM. sacrocaudalis ventralis are detailed.

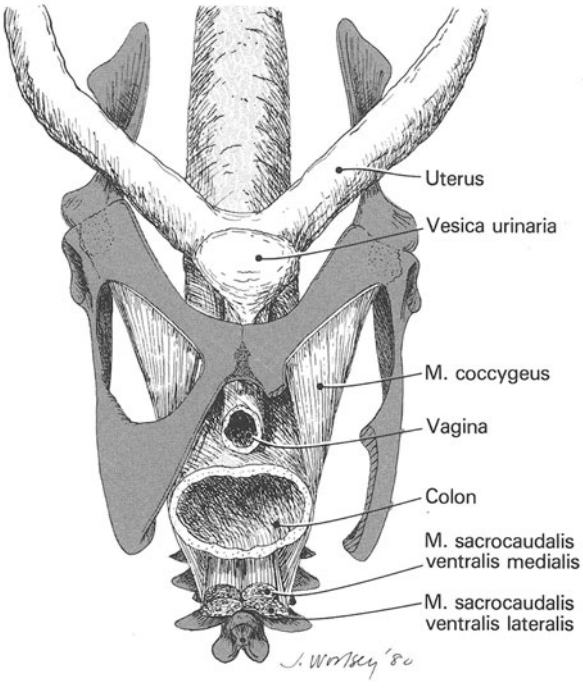

Figure 8. Musculus coccygeus and MM. sacrocaudalis ventralis, oblique caudocranial view.

The posterior division also splits into two divisions: a muscular branch (Ramus musculares and the saphenous nerve (Ram cutanei). The saphenous nerve is well-known and needs no further description here (we refer the reader to Greene, 1968). The muscular branch innervates M. quadriceps femoris (Fig. 3). M. quadriceps femoris is the well-known muscle group situated in the upper thigh and is composed of four muscles: M. vastus lateralis, M. vastus intermedius, M. vastus medialis, and M. rectus femoris. The distribution of the innervation to these muscles is detailed in Fig. 3.

B. Genitofemoral Nerve

The genitofemoral nerve (N. genitofemoralis) emerges at the level of L2 and travels caudally along the border between the psoas muscle group and the aorta. Just caudal to the aortal bifurcation (Fig. 4), it divides into two branches that pass ventral to the common iliac vein (Vena ilaca communis): the external spermatic (Ramus genitalis) and the lumboinguinal branch (Ramus femoralis). The latter branch innervates the skin of the cranial femoral triangle, the area overlying the muscles innervated by the posterior division of the femoral nerve (see Fig. 3). The external spermatic branch travels farther caudally, giving off branches to the skin of the caudal femoral triangle, through the inguinal canal, and finally innervates the skin immediately adjacent to the genitalia as well as the Labium majus (Labium pudendi) Greene, 1968).

C. Pelvic and Hypogastric Nerves

These two nerves must be described together in order to understand their anatomical relationship. The two nerves intermingle in the pelvic plexus (Plexus pelvinus) (Figs. 5, 6B) located on the lateral wall of the rectum, dorsal to the uterine junction. The hypogastric nerve (N. hypogastricus) emerges as a bilaterally paired nerve from the inferior mesenteric plexus (Plexus mesentericus caudalis) (Fig. 5), a ganglion located on the ventral surface of the inferior mesenteric artery (A. mesenterica caudalis) at the bifurcation of the aorta (Marshall, 1970).

The inferior mesenteric plexus is one of a network of sympathetic plexus and ganglia that more or less cover the ventral surface of the aorta and Vena cava (Kuntz, 1965). They receive input from the sympathetic chain ganglia via the lumbar splanchnic nerves (Nn. splanchnici lumbales). From the inferior mesenteric plexus, the nerve travels laterally and caudally, usually within a mass of fatty tissue, more or less defining the side of an ellipse formed by the iliacal vessels and the uteri. It descends dorsally from the level of the dorsal extent of the uterus to the lateral surface of the colon as it explodes into the pelvic plexus.

The pelvic nerve (N. pelvini) provides the parasympathetic component of

the plexus (Bradley *et al.,* 1974; Carlson and DeFeo, 1965; Langworthy, 1965). The nerve emerges from S1 and S2 and travels caudally and slightly laterally. It runs immediately ventral to the pudenal nerve (N. pudendus) and traverses medial to the internal iliac vein (Vena iliaca interna) as the latter descends dorsally. From there, it arches medially, coming to rest on the lateral surface of the colon. (Fig. 6A).

The pelvic plexus is a delicate structure in the female rat. From the plexus, fine strands innervate the rectum, vagina, clitoris, urethra, urinary bladder, and cervix (Langworthy, 1965). Much work has been devoted to the details of visceral innervation via the pelvic plexus both extrinsically and intrinsically (Bradley and Teague, 1972; Langley and Anderson, 1896; Marshall, 1970; Purinton *et al.,* 1973). For details, we refer the reader to these papers.

D. Pudendal and Caudal Cutaneous Femoral Nerves

Fibers arising from L6 and S1 that ultimately contribute to the pudendal plexus form a trunk that travels caudally just deep to the pelvic nerve. In fact, between the vertebrae and the internal iliacal vessels, they run duplicate courses, the only difference being that the trunk lies dorsal (i.e., "deep" in our figures) to the pelvic nerve along the way. As the pelvic nerve rises caudal to the internal iliac (Fig. 6A), the trunk dives dorsally under the ascending ramus of the pubis (Ramus cranialis os pubis), traveling between the coccygeus muscle (M. coccygeus) and the caudal flexors (Mm. sacrocaudalis ventralis) (Fig. 7B). As the trunk continues caudally, deep to the obturator foramen (Foramen obturatorum), it meets collaterals from the lumbosacral trunk (Truncus lumbosacralis) in the so-called pudendal plexus (Plexus pudendus) (Fig. 7A). The Ramus musculi coccygei, a series of delicate fibers innervating the coccygeus muscle, is given off just prior to the plexus.

The plexus itself is a fine structure that can easily be separated into its component parts. A narrow branch of the lumbosacral trunk interacts with the pudendal trunk to produce the plexus which lies deep to the caudolateral aspect of the obturator foramen. From there, two nerve groups emerge. Laterally, the caudal cutaneous femoral nerve (N. cutaneous femoris caudalis) travels to the caudal extent of the animal, innervating the skin that lies in the trough formed between the tail and thigh itself (Greene, 1968; Langley and Anderson, 1896). The medial nerve group is that of the pudendal nerve itself (N. pudendus), innervating the urethra and colon with fine branches while sending a prominent branch, the dorsal nerve of the clitoris (N. dorsalis clitoris), beneath the symphysis pubis to innervate the clitoris.

A brief mention of the relationship of the muscles of the pelvic diaphragm and the caudal flexors to the appropriate nerves will aid the reader in orienting himself and understanding the overall topography. The caudal flexors, brevis (M. sacrocaudalis ventralis lateralis) and longus (M. sacrocaudalis ventralis medialis), are shown in Fig. 8. They take their origins from the lumbar verte-

brae as far cranially as L5 and insert upon and throughout the tail (Greene, 1968). The coccygeus muscle is also illustrated in Fig. 8. It arises from the ventrocaudal ilium and inserts upon the tail with the caudal flexors (Green, 1968). The muscle known as Levator ani in many texts is absent in the female rat after day 18 of neonatal life (Hebel and Stromberg, 1976). The pudendal nerve travels medial to the coccygeus, within the pelvic diaphragm, to reach its ultimate destination. It is therefore necessary to remove much of the ventral aspect of the pelvis in order to properly visualize its intrapelvic course.

REFERENCES

Bradley, W. E., and Teague, C. T., 1972, Electrophysiology of pelvic and pudendal nerves in the cat, *Exp. Neurol.* **35**:378.

Bradley, W. E., Timm, G. W., and Scott, F. B., 1974, Innervation of the detrusor muscle and urethra, *Urol. Clin. North Am.* **1**(1):3.

Carlson, R. R., and DeFeo, V. J., 1965, Role of the pelvic nerve vs. the abdominal sympathetic nerves in the reproductive function of the female rat, *Endocrinology* **77**:1014.

Greene, E. C., 1968, Anatomy of the rat, *Trans. Am. Philosoph. Soc.* **XXVII**:1.

Hebel, R., and Stromberg, M. W., 1976, *Anatomy of the Laboratory Rat,* Williams & Wilkins, Baltimore.

Kollar, E. J., 1952, Reproduction in the female rat after pelvic nerve neuroectomy, *Anat. Rec.* **115**:641.

Kuntz, A., 1965, *Autonomic Nervous System,* Third Edition, Lea & Febiger, Philadelphia.

Langley, J. N., and Anderson, H. K., 1896, The innervation of the pelvic and adjoining viscera. Part VII: Anatomical observations, *J. Physiol. (Lond.)* **20**:372.

Langworthy, O. R., 1965, Innervation of the pelvic organs of the rat, *Invest. Urol.* **2**:491.

Marshall, J. M., 1970, Adrenergic innervation of the female reproductive tract: Anatomy, physiology and pharmacology, *Ergeb. Physiol.* **62**:6.

Purinton, P. T., Fletcher, T. F., and Bradley, W. E., 1973, Gross and light microscopic features of the pelvic plexus in the rat, *Anat. Rec.* **175**:697.

World Association of Veterinary Anatomists, 1973, *Nomina Anatomica Veterinaria,* Second Edition, International Committee on Veterinary Nomenclature, Vienna.

Index